

Infrarenal Aortic Stenosis

Prof. Dr. C. Manke and Dr. R. Hüttinger
Diagnostic and Interventional Radiology, Fulda Clinic

Stent used: 22 mm x 80 mm

sinus-XL

CASE REPORT

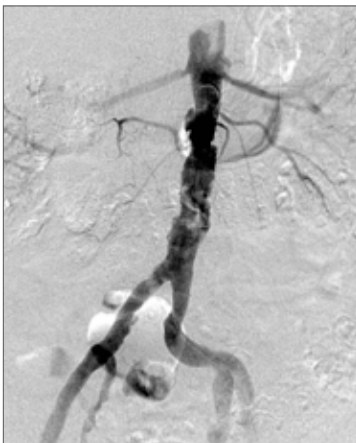


1. Introduction

Operative treatment of stenoses and occlusion of the infrarenal aorta involves major abdominal surgery which is not wholly free from risk owing to the frequent occurrence of a combination of risk factors (COPD, CHD). In comparison to operation, the use of stents in interventional treatment of aorto-iliac lesions results in comparable patency rates at lower levels of treatment risks.

2. Case study

An 87-year-old patient was admitted for claudication of the buttocks and both thighs. Risk factors comprised nicotine abuse, high blood pressure, diabetes mellitus requiring insulin treatment and three-vessel CHD; the patient's medical history included anterior myocardial infarct and COPD.



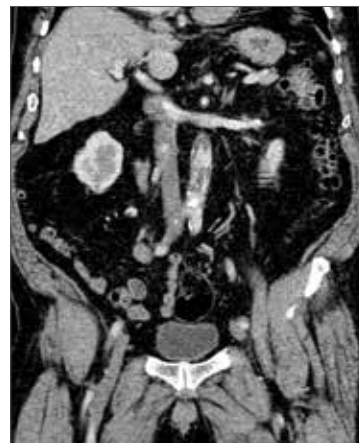DSA of abdominal aorta showing unspectacular infrarenal aortic stenosis.

No relevant lesions were seen upon progressing in a distal direction.

The ankle-brachial index indicated right 0.78 and left 0.71. In a cardiac treadmill test the patient was forced to stop after 90 metres owing to pain in the thighs and buttocks. A diagnostic angiogram showed a 5 cm major infrarenal aortic stenosis. The remaining pelvic and femoral circulatory systems were unobstructed. An additional computer tomography scan confirmed serious infrarenal aortic stenosis with calcified plaques and thrombotic layers. At the interdisciplinary vascular conference, an indication for interventional treatment of the aortic stenosis was established.

3. Treatment

Under local anaesthetic: femoral introduction of a long 10 F tube on the right and 6 F tube on the left. Passage of the wire and catheter was complicated by fissured infrarenal plaques. Primary implantation of a sinus-XL Nitinol stent (22 mm / 8 cm) followed. The stent was positioned below an accessory left renal artery up to a point shortly above the aortic bifurcation, to cover all degenerated sections of the infrarenal aorta. To ensure effective iliac drainage, the aortic stent was extended bilaterally into both pelvic arteries with two 12 mm / 4 cm Nitinol stents. The aortic stent was dilated at 14 mm, the iliac stents at 10 mm. Post-intervention DSA examination showed regular expansion of the stent in the infrarenal aorta without residual stenosis or peripheral embolisms.



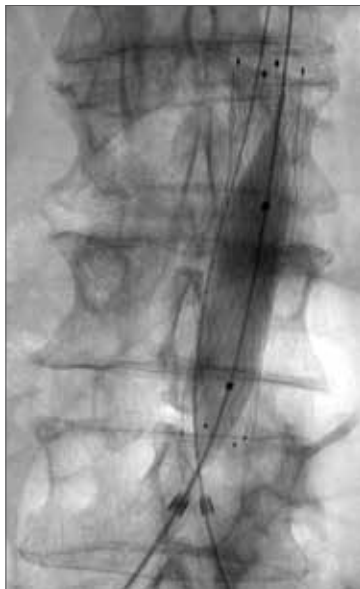Complementary CT examination of abdominal aorta to grade the stenosis and measure the length and diameter of the vascular segment to be treated.

In conclusion, both puncture points were closed with a collagen closure device with primary hemostasis and a pressure dressing was applied. During the operation 5000 E of heparin and a single-shot antibiotic with 1.5 g of cefuroxim were administered.

Existing treatment with ASS 100 was continued. Post-interventional progress was free from complications. Doppler examination showed an ankle brachial index of 0.93 right and 1.1 left. The patient was free from symptoms upon discharge.

4. Summary and critical evaluation

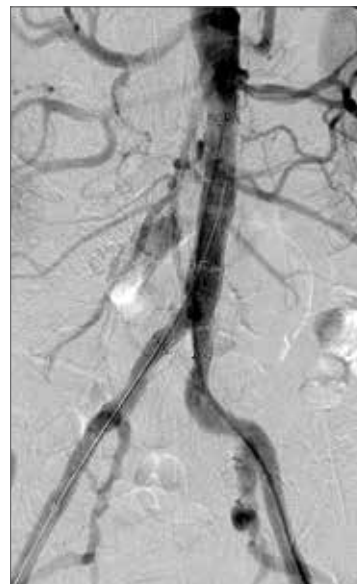The high-risk patient was successfully treated for major long eccentric calcified stenosis of the infrarenal abdominal aorta by the introduction of a sinus-XL Nitinol stent. No reliable data concerning the benefits of stenting compared to dilation only is available for cases of stenoses of the infrarenal aorta. Given the length of the eccentric stenosis, primary stent treatment appeared to be indicated given the anticipation of good primary technical results and lower risk of embolism.



Dilation of the implanted sinus-XL with easily visible tantalum markers at the stent ends

The sinus-XL is the only nitinol stent available for long lesions in major arteries (aorta, v. cava). Its closed-cell design ensures that plaque is well covered, thus lowering the risk of embolism, and that passage of a balloon catheter for subsequent dilation is smooth. The stent has tantalum markers at the ends and is easily visible even in adipose patients. Its 10-French compatibility enables the puncture point to be closed with a common closure device.

optimed would like to thank Prof. Dr. C. Manke and Dr. R. Hüttinger, Diagnostic and Interventional Radiology, Fulda Clinic, for their kind help and support and provision of X-ray images.



Concluding DSA check-up after stenting of the infrarenal aortic stenosis and extension into both pelvic arteries using nitinol stents